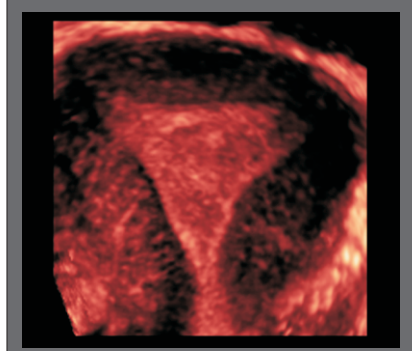


APPLICATIONS AND ADVANTAGES OF 3-D ULTRASOUND IN IMAGING OF THE UTERUS

Two Dimensional Ultrasound (2D US) is widely used to solve diagnostic problems in gynecology. Sonologists routinely use cross sectional ultrasound information to develop a mental 3-Dimensional image of the pelvic anatomy. However the ability to obtain certain views of the pelvic organs with 2 D US is limited.

The advantage of 3D Ultrasound (3D US) is that any desired plane through a pelvic organs can be obtained. The coronal "Face on" view of the uterus and endometrium which is rarely seen with 2D US, can easily be obtained by 3D US. Thus 3-Dimensional Multi-planar and Multi-slice Contrast Imaging along with special techniques such as VOCAL (3D volume calculation) is very successfully used to examine the uterus to diagnose and classify uterine anomalies, to measure endometrial volume and locate fibroids and define their relation to the endometrial canal.

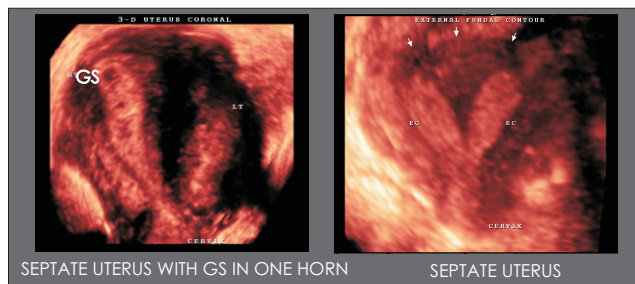
NORMAL CORONAL VIEW OF UTERUS



In this newsletter we review the current and potential future applications of 3-DUS in imaging of the uterus.

Clinical Applications :

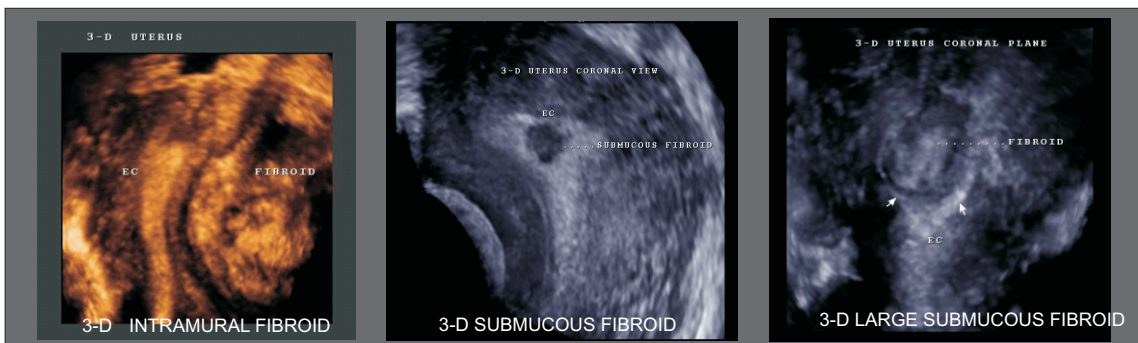Uterine Anomalies : The precise classification of the anomaly is of clinical importance as the need for intervention and type of intervention depends on the severity of the anomaly. 3D US provides detailed information about the external and internal contours of the uterus making accurate classification of the anomaly possible. Several studies have proven the specificity and sensitivity of 3D US for diagnosing uterine anomalies to be 100%.



SEPTATE UTERUS WITH GS IN ONE HORN

SEPTATE UTERUS

Fibroids : Uterine myomas can be very well assessed by 3D US. The Multiplanar display, especially the coronal view allows precise localization of a fibroid with respect to the endometrial canal. This information can assist the clinician in planning the surgery and the surgical approach. Diagnosis and detailed evaluation of submucous fibroids is also possible with 3D US.



3-D INTRAMURAL FIBROID

3-D SUBMUCOUS FIBROID

3-D LARGE SUBMUCOUS FIBROID

ADVANCED RADIOLOGY CENTRE
ARC
STATE-OF-THE-ART CARE
NEWS LETTER
AUGUST-2005

ONE STEP
AHEAD IN
ULTRASOUND
IMAGING...
3D + 4D
IMAGING

FACILITIES:-

- WHOLE BODY-ULTRASOUND
- COLOR DOPPLER
- MAMMOGRAPHY
- BMD-DEXA
- CT-SCAN
- DIGITAL X-RAY
- ECHO CARDIOGRAPHY
- PATHOLOGY

Add :

4, Royal Sands,
'A' wing, Near Fame
Adlab, New Link Rd,
Andheri-(W), Mumbai.
Tel: **2630 55 67/68/69**

E-mail:

arcbombay@vsnl.net

Web-Site

www.arcbombay.net

Timings:

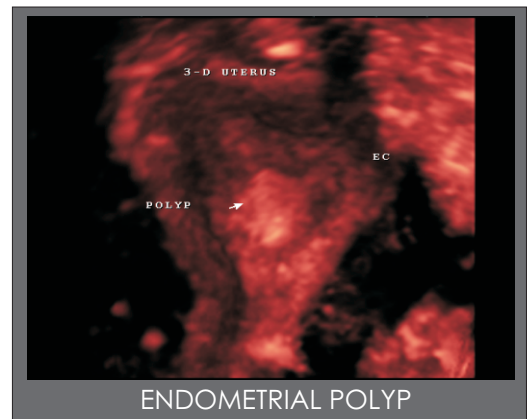
9.00 am to 8.00 pm

**ADVANTAGES
 OF
 3-D ULTRASOUND
 IN IMAGING
 OF THE PELVIS**

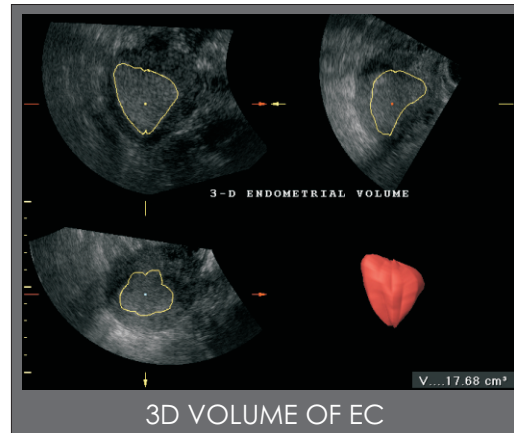
- ANY DESIRED IMAGING PLANE POSSIBLE
- VOLUME, RATHER THAN SLICE OF USG INFORMATION OBTAINED.
- 3 ORTHOGONAL PLANES AXIAL, SAGITAL AND CORONAL CAN BE SIMULTANEOUSLY VIEWED.
- ACCURATE 3-D VOLUME CALCULATION POSSIBLE.
- 3D USG USEFUL FOR REINFORCING INITIAL DIAGNOSTIC IMPRESSIONS.

Endometrium and Endometrial Canal:

The Multiplanar display provided by 3D US permits clear visualization of the triangularly shaped endometrium and depicts the cornual angles, the myometrial-endometrial border and entire cervical canal. Better identification of tiny endometrial polyps is possible with 3D US.

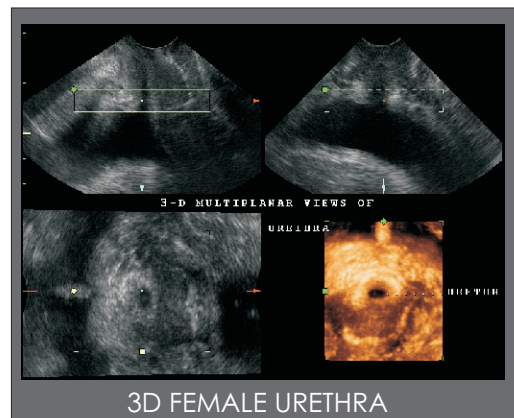
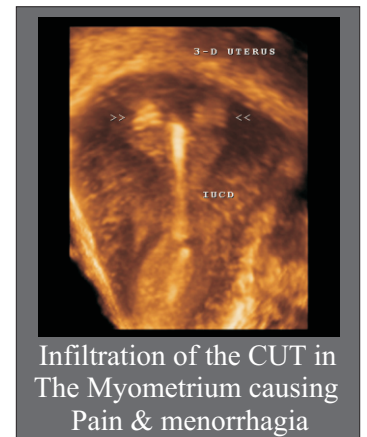


With 2D US, single measurement of the endometrial thickness is used to differentiate between normal and abnormal endometria. However there is overlap



between the endometrial thickness in benign and malignant conditions. **Endometrial volume measured with 3D US (Vocal) is a potentially more accurate parameter with a sensitivity of 100% and specificity of 98% for diagnosing endometrial carcinoma using a cutoff of 13 cc.**

Visualization of the endometrial canal in the coronal plane provides more comprehensive assessment of the Location of IUCD's.



In the near future examination of the female pelvic floor and the urethra will also be possible for evaluation of stress incontinence.

In conclusion 3D US does not replace 2D US but rather extends its capabilities. 3D US of the female pelvis is rapidly gaining popularity and has been shown to offer advantages in various clinical settings.

References:

1. Steiner H, Staudach A, Spitzer D, Schaffer H. Three-dimensional ultrasound in obstetrics and gynecology : technique, possibilities and limitations. *Hum Reprod* 1994; 9:1773-1778. *Journal of Ultrasound In Medicine*
2. Nelson T, Downey D, Pretorius D, Fenster A. Three-Dimensional Ultrasound. Philadelphia, PA: Lippincott Williams & Wilkins : 1999. *Journal of Ultrasound In Medicine*
3. Raine-Fenning N, Campbell B, Collier J, Brincat M, Johnson I. The reproducibility of endometrial volume acquisition and measurement with the VOCAL imaging program. *Ultrasound Obstet Gynecol* 2002; 19:69-75. *Journal of Ultrasound In Medicine*